ELSEVIER
SAUNDERS

Clin Chest Med 25 (2004) 455–465

CLINICS
IN CHEST
MEDICINE

Imaging of interstitial lung disease

Sudhakar Pipavath, MD*, J. David Godwin, MD

Department of Radiology, University of Washington Medical Center, Radiology Box 357115, Seattle, WA 98195-7115, USA

The pulmonary interstitium is affected by a broad group of diseases. Of roughly 150 diseases, only a small subset is encountered regularly. Idiopathic interstitial pneumonias, sarcoidosis, Langerhans cell histiocytosis (LCH), hypersensitivity pneumonitis, and pneumoconiosis are among the most common.

The consensus statement on interstitial pneumonias further classifies interstitial lung diseases into idiopathic interstitial pneumonias, diffuse parenchymal lung disease from known causes (eg, collagen vascular diseases), granulomatous disease (sarcoidosis), and a miscellaneous group that includes lymphangioleiomyomatosis (LAM) and LCH [1].

This article presents the imaging findings in sarcoidosis, silicosis, asbestosis, LAM, LCH, collagen vascular diseases, hypersensitivity pneumonitis, and pulmonary alveolar proteinosis (PAP) (Table 1). The idiopathic interstitial pneumonias are discussed in the second article on imaging of interstitial lung disease.

Plain radiography

Plain chest radiography that uses posteroanterior and lateral chest views is an important part of the initial imaging of diffuse lung disease. The advantages of plain radiographs include low cost, high spatial resolution, and low dose of radiation. In assessing diffuse lung disease, the goals of interpreting the chest radiograph are to: (1) determine the pattern of the lung disease; (2) recognize any abnormality of lung volume; (3) note any accompanying abnormalities, such as lymphadenopathy, pleural effusion, pleural thickening, cardiomegaly, bone or joint disease, and soft-tissue calcification; and (4) note changes from previous images.

The pattern of abnormality

Common patterns include nodular, reticular, airspace disease, or a combination of these. A reticulonodular pattern is encountered most commonly. A predominantly nodular pattern is found in sarcoidosis, silicosis, coal worker's pneumoconiosis (CWP), miliary tuberculosis or fungal infection, berylliosis, and LCH. A reticular pattern is found in idiopathic pulmonary fibrosis (IPF), asbestosis, collagen vascular disease, and chronic hypersensitivity pneumonitis. Airspace filling is the dominant pattern in cryptogenic organizing pneumonia (COP), eosinophilic pneumonia, alveolar proteinosis, vasculitis, and so-called "alveolar sarcoidosis."

Lung volumes

Upper lung volume loss is found in sarcoidosis, chronic hypersensitivity pneumonitis, silicosis, CWP, ankylosing spondylitis, and radiation pneumonitis. Lower lobe volume loss is found in IPF, asbestosis, and collagen vascular disease. Lung volumes are preserved in LAM and LCH.

Accompanying abnormalities

Associated abnormalities, such as penciling of the clavicles (in rheumatoid arthritis) or dilation of the esophagus (in progressive systemic sclerosis [PSS] or calcinous cutis, raynaud phenomenon, esophageal dysmotility, sclerodactyly, telangiectasia [CREST] syndrome) can help in diagnosis. Similarly, soft tissue

* Corresponding author.
E-mail address: snjp@u.washington.edu (S. Pipavath).

0272-5231/04/$ – see front matter © 2004 Elsevier Inc. All rights reserved.
doi:10.1016/j.ccm.2004.05.008

Table 1
Interstitial lung disease: dominant patterns and characteristic HRCT features

Type of interstitial lung disease	HRCT features	Dominant finding	Distribution	Characteristic pattern
Sarcoidosis	Hilar, mediastinal lymphadenopathy, 5–10 mm nodules, conglomerate nodules, and masses	Hilar/mediastinal nodes and pulmonary nodules	Upper and mid lung Perilymphatic distribution (peribronchovascular, subpleural)	Hilar, mediastinal adenopathy ± parenchymal nodules
Silicosis	Hilar, mediastinal lymphadenopathy, 5–10 mm nodules, conglomerate nodules, and masses	Noncalcified and calcified (egg-shell) lymphadenopathy and pulmonary nodules	Upper and mid lung	Hilar, mediastinal lymphadenopathy ± nodules and occupational history
Asbestosis	Interlobular and intralobular septal thickening, honeycombing, ground-glass opacity	Reticular abnormality	Basal and peripheral	Usual interstitial pneumonitis pattern with features (pleural plaques) or history of exposure
LAM	Discrete cysts, pleural effusion, pneumothorax	Cysts	Diffuse	Discrete cysts, preserved lung volume, chylous pleural effusion in a woman of reproductive age
LCH	Small nodules with or without cysts	Nodules in early stages and combined cystic and nodular or purely cystic forms in later stages	Upper and mid lung	Nodules, cysts in upper lungs; preserved lung volume; history of smoking
HP (acute)	Ground-glass opacity and air-trapping	Ground-glass opacity	Upper and mid lung	Ground-glass opacity and air-trapping
HP (subacute)	Fuzzy centrilobular nodules, Ground-glass opacity ± air-trapping	Fuzzy centrilobular nodules	Upper and mid lung	Fuzzy centrilobular nodules and air-trapping
HP (chronic)	Interlobular and intralobular septal thickening, traction bronchiectasis, and honeycombing	Fibrosis and upper lobe volume loss	Upper and mid lung	UIP pattern in upper- and mid-lung distribution
PAP	Ground-glass opacity with superimposed reticular "crazy-paving"	Ground-glass opacity	Often central and symmetric; may have "geographic" margination by septa of spared lobules	Ground-glass opacity

calcification may be a clue to dermatomyositis, CREST syndrome, or PSS. Mediastinal lymphadenopathy can occur with sarcoidosis or PSS. Pleural effusion points to rheumatoid disease, lupus erythematosus, or LAM. Pleural plaques indicate asbestos exposure and the possibility that basal fibrosis could represent asbestosis.

Comparison with old radiographs can help to distinguish interstitial diseases—which typically run a subacute or chronic course—from acute diseases, such as infection or edema. Comparison helps in assessing progression and response to treatment.

The limitations of plain radiographs are well-known. They include obscured or hidden lung zones; limited contrast resolution, which impairs sensitivity to subtle alterations in lung density (eg, ground-glass opacity or emphysema); and overlap and superimposition of the interstitial opacities within the lung which makes it difficult to characterize their shape and distribution. These difficulties in plain radiographic interpretation of interstitial disease were demonstrated by McLoud et al [2]. They found that the correct histologic diagnosis was predicted by the first two differential diagnoses based on plain radiography in only 50% of cases. Furthermore, there was only 70% interobserver agreement in classifying the opacities and in grading severity.

High-resolution computed tomography

The main difference between HRCT and conventional CT is the thickness of the slice, although there also are differences in image reconstruction. Conventional CT uses a slice thickness between 5 mm and 10 mm, whereas HRCT uses a thickness of 0.5 mm to 2 mm (typically 1 mm or 1.25 mm). The problem with thick slices is that all of the structures therein are imaged as if they were in a single plane. Thus, anatomic resolution is compromised and the density measurements are unreliable because the apparent density is an average made over the whole slice thickness. This degradation of density discrimination makes it difficult to detect subtle alterations of lung density, such as emphysema and ground-glass opacity.

HRCT images usually are not contiguous, but are spaced at intervals to sample different parts of the lung. The lack of contiguous images means that important findings, such as tumor nodules, can be missed. Thus, HRCT is intended for sampling of diffuse disease, rather than for scrutinizing every bit of lung; HRCT is not appropriate for all imaging tasks. Furthermore, HRCT images have to be acquired separately from conventional CT images and thus entail additional radiation dose, although low-dose HRCT can be effective. HRCT images that are acquired at 20 mA yield anatomic information that is equivalent to that obtained with 200-mA scans in most patients, without losing spatial resolution and creating streak artifacts [3]. The patient's ability to hold his breath is more critical in HRCT than conventional CT. Motion artifacts that are caused by breathing or cardiac contraction can create false positive findings, especially ground-glass opacity, pseudobronchiectasis, and double images of fissures and vessels.

A standard HRCT imaging protocol for evaluation of diffuse interstitial lung diseases includes supine and prone images in full inspiration and supine images in full expiration. Prone images are helpful in differentiating dependent atelectasis from actual lung disease. Expiratory images are useful in detecting air-trapping, which is a sign of dysfunction of small airways.

Two recent studies compared the high-resolution spiral CT scans that were obtained from a multi-slice CT scanner and sequential HRCT scans that were obtained on a single slice CT scanner [4,5]. These studies concluded that a comprehensive diagnosis is feasible in patients who have suspected focal and diffuse lung disease by obtaining a single scan (multi-slice scanner) instead of a two-step process. The investigators acknowledged, however, that the massive amount of data that is generated by this technology puts significant strain on any image analysis and archiving system. Until new modalities for data transfer, data archiving, and image interpretation are devised, multi-slice helical CT will remain underused.

The radiologist needs to have good clinical information to formulate a proper differential diagnosis. CT interpretation in interstitial lung disease depends on assessing the morphology and density of the lung abnormalities (eg, nodular, reticular, cystic, ground-glass) and their distribution in relationship to the secondary pulmonary lobule. HRCT is much better than conventional CT at these tasks.

A glossary of terms that is used in HRCT interpretation is provided in the article "*Standardized terms for high resolution computed tomography of the lung: a proposed glossary*" in the Journal of Thoracic Imaging [6].

The principal terms that we use in reporting HRCT scans include:

Air-trapping. Abnormal retention of gas within a lung or lung units following expiration.

Conglomerate mass. A large opacity that often encompasses bronchi and vessels in the central or parahilar lung.

Consolidation. An increase in lung opacity that results in obscuration of blood vessels.

Cyst. A clearly-marginated lucency with a wall that contains air, and no residual lung tissue. *Emphysema* is another cause of lucency in the lung, but an emphysematous space lacks clear margins and may contain some tissue strands, including blood vessels.

Ground-glass opacity. A hazy increase in lung opacity (compared with the density of normal lung) not associated with obscuration of underlying vessels.

Honeycombing. Cystic spaces ranging from several millimeters to several centimeters in diameter, characterized by thick, clearly definable fibrous walls, which typically are lined by bronchiolar epithelium.

Interlobular interstitial thickening. Abnormal thickening of the interlobular septae.

Intralobular interstitial thickening. Thickening of the intralobular interstitium, resulting in a fine reticular appearance to the lung parenchyma.

Nodule. A discrete, round, small opacity, ranging from 1 mm to 3 cm.

Reticulation. A network of linear strands of thickened interstitium.

Traction bronchiectasis. Bronchial dilation and irregularity occurring in patients who have pulmonary fibrosis, because of traction by fibrous tissue on the bronchial wall. True bronchiectasis is defined as irreversible bronchial dilation as a result of various causes other than fibrosis. Traction bronchiectasis probably does not cause much loss of bronchial function in terms of ciliary motility and bronchial toilet.

Anatomy of the secondary pulmonary lobule

HRCT interpretation depends on understanding the anatomy of the secondary pulmonary lobule (Fig. 1). This building block of the lung is a polyhedron that measures approximately 1 cm to 2.5 cm on a side and contains a few terminal bronchioles, which ultimately supply 3 to 12 acini (a pulmonary acinus is defined as the portion of the lung that is supplied by a first order respiratory bronchiole). Pulmonary arterioles accompany the bronchioles. The lobule is marginated by interlobular septa, which contain connective tissue, venules, and lymphatics.

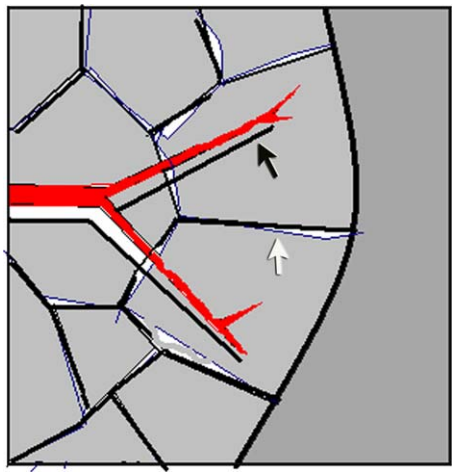

Fig. 1. Line diagram of a secondary pulmonary lobule. Note the bronchiole and pulmonary arteriole (*black arrow*) in the center and the lymphatics and venous structures (*white arrow*) in the periphery.

Sarcoidosis

Sarcoidosis is a multi-system disease with distinct intrathoracic manifestations. On plain radiographs, this disease is categorized into four stages:

Stage 0: Normal chest radiograph
Stage 1: Mediastinal and hilar lymphadenopathy
Stage 2: Lymphadenopathy with pulmonary parenchymal lesions
Stage 3: Pulmonary parenchymal lesions in the absence of hilar lymphadenopathy
Stage 4: Significant lung fibrosis with architectural distortion or bullae

Untreated patients who have stage 1 disease (Fig. 2) may have resolution of symptoms and radiographic abnormalities in 50% to 90% of cases, compared with 30% to 70% of patients who have stage 2 disease, 10% to 20% of patients who have stage 3 disease, and, as expected, 0% of patients who have stage 4 disease [7]. Many times the radiographic severity may be substantially greater than the clinical manifestations. Thus, treatment is more helpful when based on clinical symptomatology, rather than on radiographic abnormalities. Radiographic abnormalities may precede clinical symptoms in patients who relapse after a course of treatment [8].

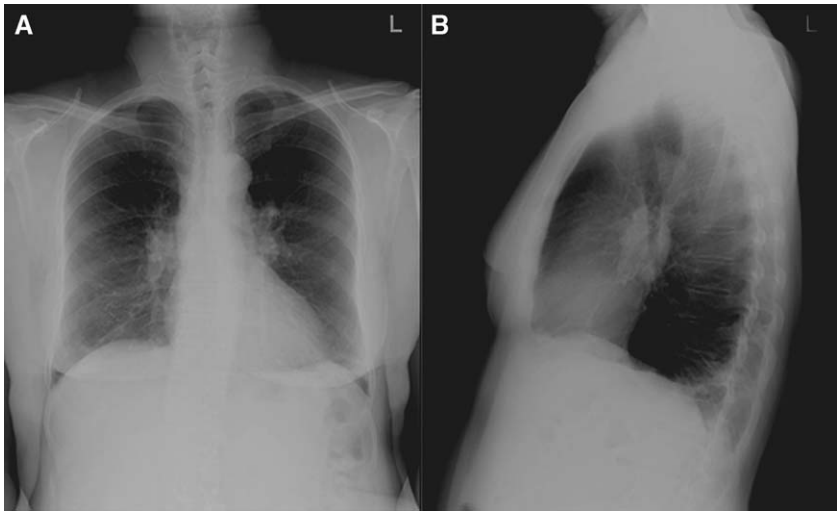

Fig. 2. Sarcoidosis. Chest radiographs (posteroanterior [*A*] and lateral [*B*]) show bilateral hilar lymphadenopathy.

CT findings in sarcoidosis can be classified broadly into typical and atypical features. Typical features include bilateral hilar and mediastinal lymphadenopathy with or without calcification. Sometimes the nodes are calcified at the periphery, creating so-called "egg-shell" calcification. Interstitial abnormalities include smooth or nodular peribronchovascular interstitial thickening and small, well-defined nodules (Fig. 3) in a perilymphatic distribution in relation to the pleural surfaces, interlobular septa, and centrilobular structures. Most nodules are in the range of 5 mm to 10 mm, but miliary nodules (Fig. 4) also occur. Larger nodules and consolidation occur uncommonly. The interstitial abnormalities are concentrated in the mid and upper lungs. In later stages, septal thickening, traction bronchiectasis, and honeycombing (Fig. 5) may occur. In some cases of severe stage 4 disease, conglomerate masses develop near the hila with surrounding paracitricial emphysema. These lesions resemble progressive massive fibrosis in complicated silicosis.

An uncommon pattern of sarcoidosis is the "acinar," "alveolar," or "nummular" (Fig. 6) form. Acinar sarcoid carries a better prognosis than the reticular form. Ipsilateral hilar lymphadenopathy may be associated with this form.

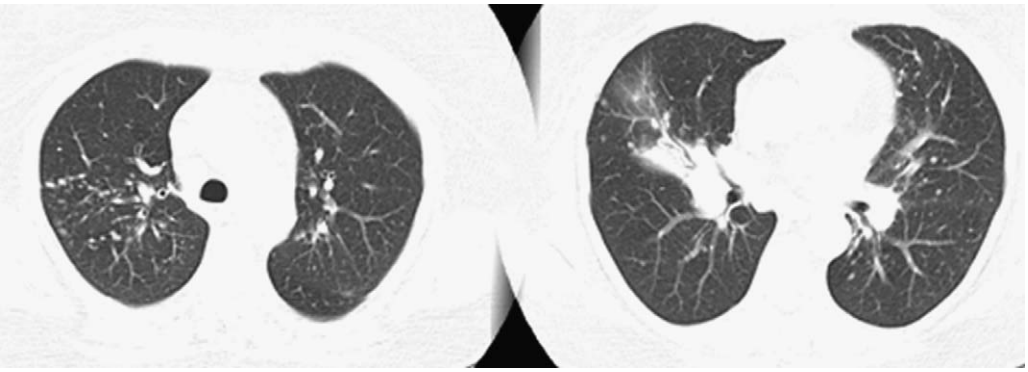

Fig. 3. Sarcoidosis. CT shows 5- to 10-mm nodules in random distribution. Also note endobronchial disease which is responsible for volume loss in middle lobe.

Fig. 4. Sarcoidosis. HRCT shows miliary nodules, an uncommon but distinctive pattern of sarcoidosis. (Courtesy of J. Takasugi, MD, Seattle, WA.)

Solitary pulmonary nodules, multiple lung masses, and cavitary nodules are uncommon manifestations. The presence of cavitary disease should prompt exclusion of other conditions, such as vasculitis, superinfection, and necrotizing sarcoidosis.

Necrotizing sarcoid granulomatosis, first described by Liebow [9], consists of confluent granulomas with or without central necrosis associated with a necrotic granulomatous vasculitis of the pulmonary vessels. It differs from Wegener's granulomatosis in the extensive nature of the sarcoid-like reaction and in its benign clinical course.

Silicosis, CWP, and berylliosis have features that mimic sarcoidosis. Silicosis and CWP tend to be more symmetric than sarcoidosis. Upper lung predominance and conglomerate masses can occur in each of these conditions.

Silicosis

Silicosis is caused by inhalation of dust that contains crystallized silicon dioxide. An appropriate history of exposure, combined with characteristic findings on chest radiographs, often suffices to make the diagnosis.

Simple silicosis

On chest radiographs and on CT scans the characteristic finding is small nodules that range from 3 mm to 10 mm. Nodules are concentrated in the upper lungs with a centrilobular and, sometimes, subpleural predilection; this suggests a perilymphatic distribution (Fig. 7) [10]. CT may show a posterior predominance. Hilar or mediastinal lymphadenopathy may occur, with or without calcification; a characteristic feature is egg-shell calcification, as in sarcoidosis.

Complicated silicosis

In complicated silicosis, the individual small nodules have begun to pull together and coalesce because of scarring. The advanced form of this coalescence is progressive massive fibrosis, which consists of dense masses of consolidation (conglomerate masses which form near the hila) on a background of small nodules. Conglomerate masses may develop central necrosis and cavitation, which is unusual in sarcoidosis and CWP. Apical scarring, bullae, and paracicatricial emphysema often accompany silicosis.

CWP and silicosis may be distinct diseases; however, radiographic features are similar. Without appropriate history, distinction by radiographic features is difficult.

Asbestosis

Pleural plaque is the characteristic finding of asbestos exposure (Fig. 8). Diffuse pleural thickening also may occur, but is much less specific for asbestos exposure. Diffuse pleural thickening can result in round atelectasis in the adjacent lung.

Asbestosis is lung fibrosis that results from asbestos exposure. It can be distinguished from other kinds of lung fibrosis if pleural plaques are demonstrated. CT is superior to plain radiography in detec-

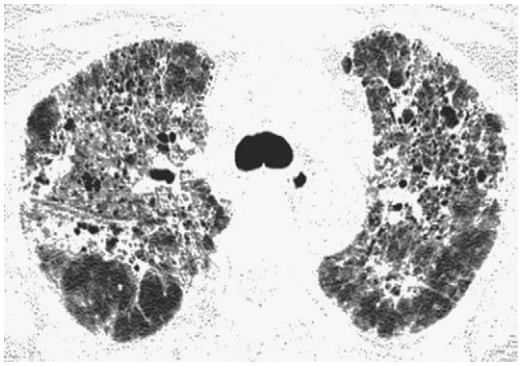

Fig. 5. Sarcoidosis (late, fibrotic stage). HRCT shows fibrosis and honeycombing in the upper lungs on both sides.

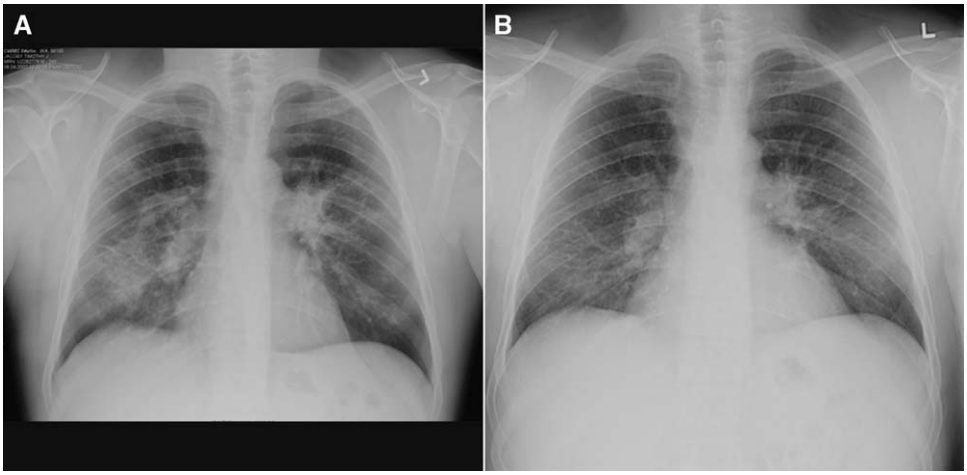

Fig. 6. "Alveolar" sarcoidosis: Pre- (*A*) and posttreatment (*B*) chest radiographs show airspace opacities and bilateral hilar lymphadenopathy. There is significant resolution on the posttreatment radiograph.

tion of pleural and pulmonary manifestations of asbestos exposure, and HRCT is better still [11]. The interstitial abnormalities are concentrated at the bases and periphery and consist of interlobular septal thickening, intralobular interstitial thickening, honeycombing, and parenchymal bands (Fig. 9). Ground-glass opacity was believed to be an early finding that is caused by thickening of alveolar walls; however, ground-glass opacity has many other causes, including simple atelectasis. HRCT is sensitive to early detection of these findings but its specificity is variable. Aberle et al [11] found good correlation between CT scores and pulmonary function impairment.

Lymphangioleiomyomatosis

LAM is a disorder of women of reproductive age (17–50 years) [12]. It is characterized by proliferation of spindle cells in lung tissue. Proliferation around bronchioles leads to development of cysts. Involvement of the lymphatics may cause obstruction and accumulation of chylous pleural effusions.

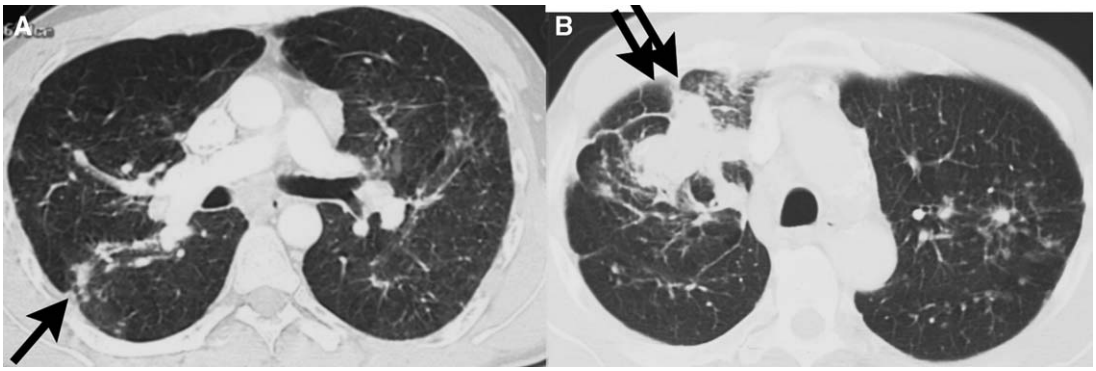

Fig. 7. Silicosis. Simple silicosis with 5- to 10-mm nodules in both upper lungs (*A*). Some of the nodules show early conglomeration (*single arrow*). Advanced silicosis (*B*) with multiple nodules and a large lung cancer in the right upper lobe (*double arrow*).

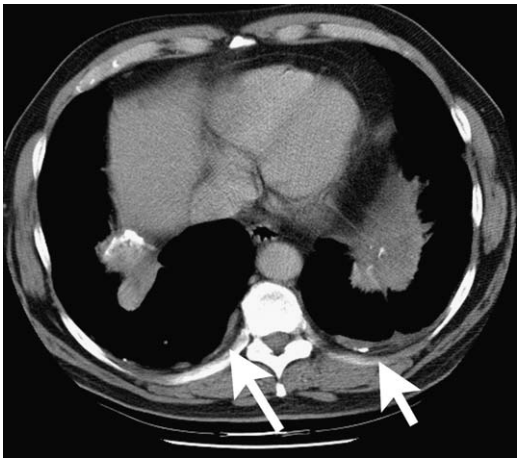

Fig. 8. Asbestos pleural plaque and pleural thickening. There are calcified and noncalcified pleural plaques (*arrows*), including calcified plaque along the right hemidiaphragm.

CT features include thin-walled lung cysts with intervening normal lung tissue (Fig. 10). The cysts occur throughout the lung and lung volume is preserved. The presence of pleural effusion helps to distinguish the cystic lung disease from LCH. Intra-abdominal manifestations include renal angiomyolipomas, lymphangiomatosis, and lymphadenopathy.

Langerhans cell histiocytosis

LCH is an idiopathic disease of young or middle-aged adults, who present with cough and dyspnea. As many as 90% [13] of these patients are cigarette smokers and there is a slight male predominance. Pneumothorax is the presenting manifestation in up to 20% of cases.

Common features on CT include nodules of 1 mm to 5 mm diameter in a peribronchiolar (centrilobular) distribution (Fig. 11). These nodules may cavitate. Thin-walled lung cysts (Fig. 12), which usually are less than 10 mm in diameter, are the other common finding in later stages. Nodules and cysts are concentrated in mid and upper lungs; characteristically, the costophrenic angles are spared on chest radiographs. Many cases resolve if the patient stops smoking. Follow-up CT scans may show regression of nodules, whereas any cysts that have formed are permanent. In cases that do not resolve, scarring may supervene which results in reticulation, thickening of the cyst walls, and architectural distortion with an upper lung concentration. Pulmonary arterial hypertension may develop.

In LCH, cysts tend to spare the basal parts of the lung near the costophrenic angles, whereas in LAM, they occur throughout the lung. In both conditions, lung volumes are preserved and pneumothorax can occur. The presence of pleural effusion helps to distinguish LAM from LCH.

Collagen vascular diseases

Rheumatoid arthritis associated interstitial lung disease, PSS, and CREST syndrome are the principal entities that affect the lung.

Rheumatoid arthritis associated interstitial lung disease

More than 75% of patients who have rheumatoid arthritis have extra-articular manifestations. In the thorax, pleural effusion is the most common; however, lung disease occurs in up to 20% of patients [14,15]. These include interstitial pneumonitis (COP, usual interstitial pneumonia [UIP], nonspecific interstitial pneumonia [NSIP]), pulmonary vascular disease (eg, pulmonary arterial hypertension), bronchiectasis and bronchiolitis (specifically, follicular bronchiolitis), and drug reactions (eg, hypersensitivity pneumonitis from methotrexate).

Necrobiotic nodules in the lung are rare. Typically, they affect men who have advanced joint disease and usually are asymptomatic [16]. They are well-

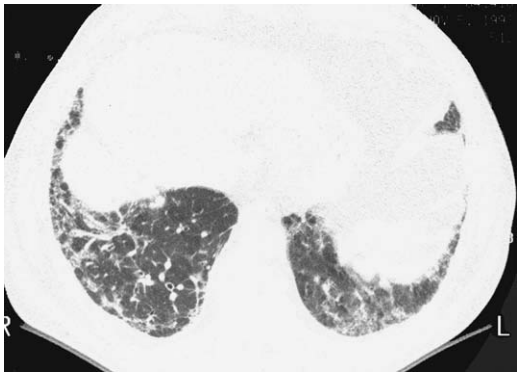

Fig. 9. Asbestosis. Basal and peripheral intralobular and interlobular fibrosis. Pleural plaques are not visible on this lung window.

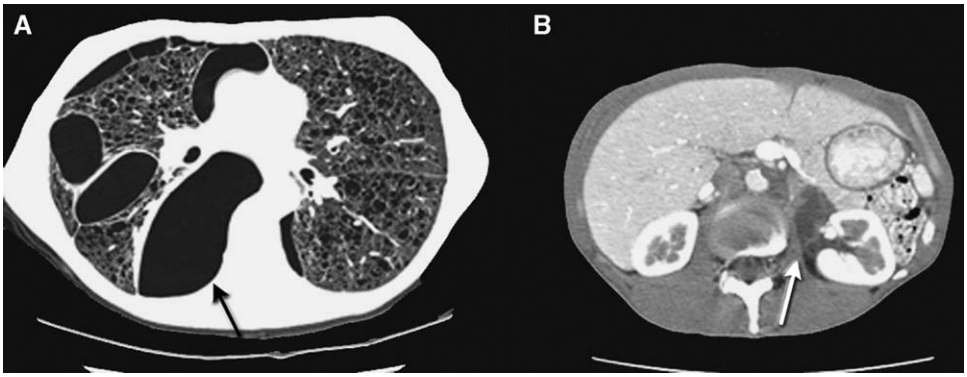

Fig. 10. LAM. HRCT image shows multiple cysts with interspersed normal lung (*A*) and right pneumothorax (*black arrow*). CT of the abdomen (*B*) shows low-attenuation retroperitoneal masses caused by lymphangiomas (*white arrow*).

defined and may cavitate. Caplan's syndrome is a syndrome of multiple necrobiotic nodules in coal miners who have rheumatoid arthritis.

Progressive systemic sclerosis and CREST syndrome

HRCT shows some degree of interstitial disease in a substantial number of these patients and may be used for monitoring the disease over time [17]. The most common abnormalities that are seen on CT are peripheral and basal ground-glass opacities and fibrosis, pleural or pericardial effusion, esophageal dilation, mediastinal lymphadenopathy, and, sometimes, pulmonary arterial dilation that reflects pulmonary hypertension.

Hypersensitivity pneumonitis

Hypersensitivity pneumonitis (HP) is caused by exposure to various occupational and environmental antigens [18]. Its diagnosis is based on clinical, radiographic, cytologic, and histopathologic findings. Clinical and radiographic features often are characteristic enough to make the diagnosis.

In the acute and subacute stages, the predominant abnormalities on HRCT are ground-glass opacities (Fig. 13) and ill-defined centrilobular nodules (reflecting inflammation around small airways) (Fig. 14). The ground-glass opacities may be concentrated in the centers of the secondary pulmonary lobules with sparing of the periphery. Small airway dysfunction can lead to air trapping that becomes visible on

Fig. 11. LCH. CT image shows noncavitary and cavitary nodules in both upper lungs.

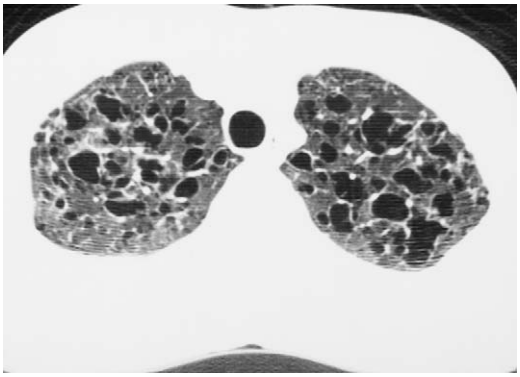

Fig. 12. LCH. CT shows multiple cysts of variable sizes in both upper lungs, a late and irreversible finding.

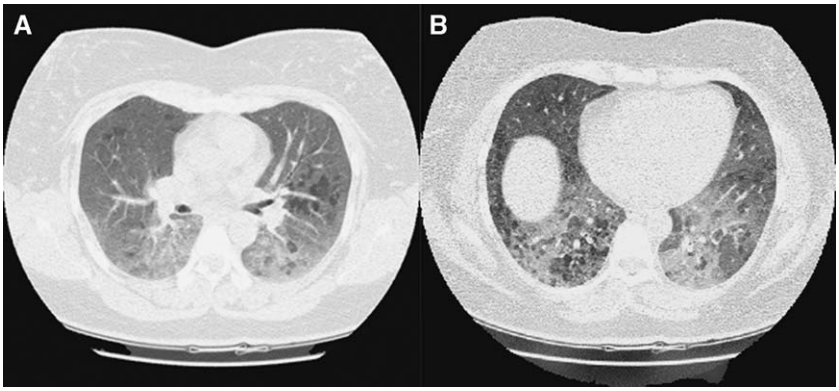

Fig. 13. Acute HP. HRCT images (inspiratory and expiratory) show ground-glass opacity (*A*) with interspersed low-attenuation regions indicating air-trapping (*B*).

expiratory HRCT scans as a mosaic pattern (see Fig. 13). In late stages, fibrosis and emphysema may develop.

Plain films often show no definite abnormality in HP, despite dramatic findings on HRCT. For this reason, the physician should have a low threshold for ordering HRCT when HP is a consideration.

Pulmonary alveolar proteinosis

In PAP, a proteinaceous material accumulates in the alveolar air spaces and causes hypoxemia, restrictive lung disease, and dramatic abnormalities on chest radiographs. Complications are unusual, but of the ones that do occur, infection (particularly with nocardia asteroids) and fibrosis are the most common. Varying combinations of air-space and interstitial patterns may be seen [19]. The CT appearance is of bilateral, symmetric alveolar consolidation or ground-glass opacity, particularly in a perihilar or hilar distribution. Typically, HRCT shows diffuse ground-glass attenuation with superimposed intra- and interlobular septal thickening, often in polygonal shapes (Fig. 15) that are known as "crazy-paving" [20]. Some lobules are spared and the sharp margination of the ground-glass opacity by the interlobular septa of the spared lobules is called "geographic" distribution, because it resembles continents that are marginated by oceans on a map.

Fig. 14. Subacute HP. Ill-defined centrilobular ground-glass opacities in upper lungs, in combination with the right clinical presentation, suggest subacute HP.

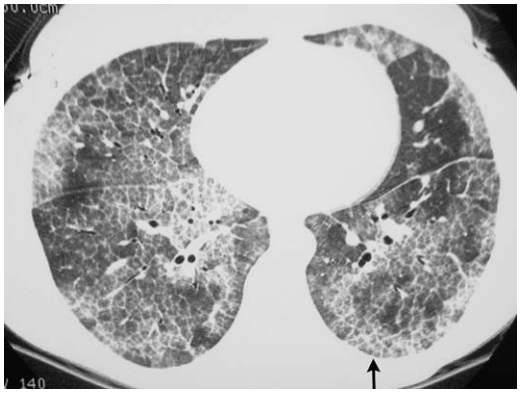

Fig. 15. PAP. HRCT image shows typical ground-glass opacity with superimposed "crazy-paving" pattern (*arrow*). Crazy-paving is the meshwork of lines that represent reversible intralobular and interlobular interstitial thickening by edema and cells.

References

[1] American Thoracic Society/European Respiratory Society International Multidisciplinary Consensus Classification of the Idiopathic Interstitial Pneumonias. Am J Respir Crit Care Med 2002;165:277–304.
[2] McLoud TC, Carrington CB, Gaensler EA. Diffuse infiltrative lung disease: a new scheme for description. Radiology 1983;149:353–63.
[3] Zwirewich CV, Mayo JR, Muller NL. Low-dose high-resolution CT of lung parenchyma. Radiology 1991; 180:413–7.
[4] Mehnert F, Pereira PL, Dammann F, et al. High resolution multislice CT of the lung: comparison with sequential HRCT slices. Rofo Fortschr Geb Rontgenstr Neuen Bildgeb Verfahr 2000;172(12):972–7.
[5] Schoepf UJ, Bruening RD, Hong C, et al. Multislice helical CT of focal and diffuse lung disease: comprehensive diagnosis with reconstruction of contiguous and high-resolution CT sections from a single thin-collimation can. AJR Am J Roentgenol 2001;177(1): 179–84.
[6] Webb WR, Muller NL, Naidich DP. Standardized terms for high-resolution computed tomography of the lung: a proposed glossary. J Thorac Imaging 1993;8:167–75.
[7] Lynch JP, Kazerooni EA, Gay SE. Pulmonary sarcoidosis. Clin Chest Med 1997;18:755–85.
[8] Baumann MH, Strange C, Sahn SA. Do chest radiographic findings reflect the clinical course of patients with sarcoidosis during corticosteroid withdrawal? AJR 1990;154:481–5.
[9] Liebow A. Pulmonary angiitis and granulomatosis. Am Rev Respir Dis 1973;108:1–18.
[10] Begin R, Ostiguy G, Fillion R, et al. Computed tomography scan in the early detection of silicosis. Am Rev Respir Dis 1991;144:697–705.
[11] Aberle DR, Gamsu G, Ray CS, et al. Asbestos related pleural and parenchymal fibrosis: detection with high resolution CT. Radiology 1988;166:729–34.
[12] Sullivan E. Lymphangiomyomatosis: a review. Chest 1998;114:1689–703.
[13] Desai SR, Ryan SM, Colby TV. Smoking-related interstitial lung diseases: histopathological and imaging perspectives. Clin Radiol 2003;58:259–68.
[14] Gabbay E, Tarala R, Will R, et al. Interstitial lung disease in recent onset rheumatoid arthritis. Am J Respir Crit Care Med 1997;156:528–35.
[15] Hurd ER. Extra-articular manifestations of rheumatoid arthritis. Semin Arthritis Rheum 1979;8:151–76.
[16] Ellman P, Ball R. Rheumatoid disease with joint and pulmonary manifestations. Br Med J 1948;2(8):16–9.
[17] Remy-Jardin M, Remy J, Wallert B, et al. Pulmonary involvement in progressive systemic sclerosis: sequential evaluation with CT, pulmonary functions and bronchoalveolar lavage. Radiology 1993;189:499–506.
[18] Glazer CS, Rose CS, Lynch DA. Clinical and radiologic manifestations of hypersensitivity pneumonitis. J Thorac Imaging 2002;17:261–72.
[19] Godwin JD, Muller NL, Takasugi JE. Pulmonary alveolar proteinosis: CT findings. Radiology 1988;169: 609–13.
[20] Rossi SE, Erasmus JJ, Volpacchio M, et al. Crazy-paving" pattern at thin-section CT of the lungs: radiologic-pathologic overview. Radiographics 2003;23: 1509–19.